

## THE HAND PATIENT

Having had the pleasure to teach and train students for many years, and the privilege of having patients referred to me by ex-student General Practitioners, one realizes that medical school training can only impart but a general overview of knowledge. It is impossible and unfair to expect of any medical student to "know it all".

For this reason, Continuing Professional Development (CPD) is imperative. This post-graduate training should however, be presented in such a way that the busy practitioner readily has access to the relevant information in a succinct form and in an understandable jargon. This continuing education is part of the responsibilities of a consultant specialist.

Communication between the specialist and the referring doctor should not only include information regarding that particular patient, but should also contain some informative detail on the pathology and management.

It is sincerely hoped that this edited collection of selected case reports will promote a well informed communication between the practitioner and his/her "hand patient".

Mennen, U.

MBChB, FRCS (Glasg), FRCS (Edin), FCS (SA) Orth., MMed (Orth), MD (Ort) Pret  
Head: Department Hand- and Microsurgery, MEDUNSA

## OSTEO-ARTHRITIS OF THE SCAPHOID-TRAPEZIUM-TRAPEZOID JOINT (STT JOINT) OF THE WRIST

Dear Colleague,

Re: Your patient with pain on the radial side of his right wrist

Thank you for your referral of Mr. J T a forty-seven year old right-handed salesman who has been complaining of pain in his right wrist for the last few years. He is uncertain about the exact period, since the pain has gradually come on and has slowly increased to the point that he now has difficulty in driving and doing his work as a salesperson in a hardware shop. He cannot remember a specific incident in the past of having hurt his wrist, although as a school child he did participate in contact sport. He also plays the guitar, which has become increasingly difficult and painful. Even the odd jobs at home

become a burden because of the pain which he experiences. He finds that resting the wrist gives him pain relief and taking anti-inflammatory drugs certainly does make it easier. He does not have any other joint involvement.

On examination Mr. T clearly has a painful wrist on the radial side and especially so when being palpated in the distal part of the snuffbox. When the "Kirk Watson" test is performed i.e. the scaphoid tubercle is resisted during radial deviation of the wrist he experiences the typical deep aching pain in his wrist, just distal to the scaphoid. Further examination of the wrist does not reveal any tender areas. He does not suffer from a first carpo-metacarpal joint osteo-arthritis or de Quervain teno-synovitis.

Special investigations involve plain x-rays of both hands and wrists i.e. postero-anterior, lateral and oblique. It is quite evident when comparing the right side with the left, normal, non-tender wrist that Mr. T has involvement of the joint between the scaphoid head, trapezium and trapezoid (STT joint). One can see narrowing of the joint space as well as subchondral sclerosis and squaring of the scaphoid head. There is no evidence of any osteo-arthritic involvement of other joints seen on the x-rays.

The diagnosis is osteo-arthritis of the STT joint. This condition is often isolated and occurs spontaneously. Since the head of the scaphoid is involved in all the movements of the wrist,

pain is experienced in nearly all activities of daily living and work.

The treatment involves conservative management in the first instance. A simple wrist-supporting splint should give pain relief. One could also attempt one or two local cortisone injections with a long-acting local anaesthetic into the STT joint. It is difficult to find the joint and the injections are usually very painful. The pain relieving effect often lasts only a few months. One should be careful not to pierce the radial artery, which lies in this area. Anti-inflammatory drugs are of some help but may only be of limited value. Local application of non-steroidal anti-inflammatory drugs is of very little help since this is a deep joint.

Should the conservative measures be unsuccessful or the patient cannot work with the splint on, the only further option is surgical intervention. A number of procedures have been described. STT arthrodesis still has its supporters although achieving an

arthrodesis of this joint is not easy and the post-operative immobilization is long, making this a procedure with a high morbidity. My personal choice is "amputation" of the distal pole of the scaphoid. This allows one to do a debridement of the joint as well as removing osteophytes. One also has the option of doing a synovectomy of the flexor carpi radialis, which is often involved and may be part of the symptom complex. After surgery a splint for two weeks is all that is needed. Patients have immediate pain relief, with very little discomfort.

#### Discussion

STT osteo-arthritis is often seen as an isolated arthritic development, which occurs spontaneously. However it could also be seen with osteo-arthritis of the first carpo-metacarpal joint.

STT arthrodesis has been popularized by Kirk Watson. However, the biomechanics of the wrist after this limited arthrodesis is changed to such a degree that generalized osteo-

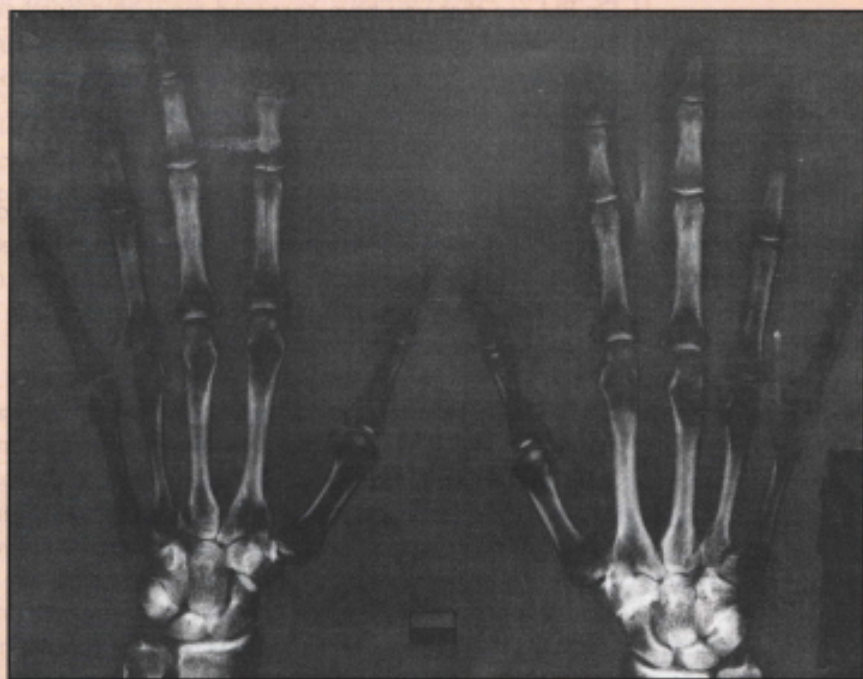
arthritis of the wrist is often seen after a few years. The incidence of non-union is high and the post-operative management usually prolonged.

Amputation of the distal third of the scaphoid is a much more simple procedure, disturbs the biomechanics of the wrist joint less and allows full inspection of the area for a synovectomy and a debridement.

Should STT osteo-arthritis occur with first carpo-metacarpal joint osteo-arthritis, both conditions could be dealt with at the same time by an excision arthroplasty of the trapezium, which should also include removing a triangular piece from the trapezoid. If this is not done patients may still complain of pain after the arthroplasty.

*With sincere regards,*

*Ulrich Mennen*



#### Legend:

Osteo-arthritis of the tri-scapho or S.T.T (Scaphoid-trapezium-trapezoid) joint may occur spontaneously and as an isolated joint involvement. Many however, occur in conjunction with osteo-arthritis of the first carpo-metacarpal joint.