

THE HAND PATIENT

Having had the pleasure to teach and train students for many years, and the privilege of having patients referred to me by ex-student General Practitioners, one realizes that medical school training can only impart but a general overview of knowledge. It is impossible and unfair to expect of any medical student to "know it all".

For this reason, Continuing Professional Development (CPD) is imperative. This post-graduate training should however, be presented in such a way that the busy practitioner readily has access to the relevant information in a succinct form and in an understandable jargon. This continuing education is part of the responsibilities of a consultant specialist.

Communication between the specialist and the referring doctor should not only include information regarding that particular patient, but should also contain some informative detail on the pathology and management.

It is sincerely hoped that this edited collection of selected case reports will promote a well informed communication between the practitioner and his/her "hand patient".

Mennen, U.

MBChB, FRCS (Glasg), FRCS (Edin), FCS (SA) Orth., MMed (Orth), MD (Ort) Pret
Head: Department Hand- and Microsurgery, MEDUNSA

VOLAR GANGLION OF THE WRIST

Dear Colleague,

RE: Your patient with a tender swelling on the volar aspect of the right wrist

Thank you for your referral of Ms P.L.L a 29 year old right hand dominant sales lady who complains of a firm swelling on the radial aspect of the flexor surface of the right wrist. This swelling has been present for about three months. The swelling has disappeared once completely but has reformed again and now seems to be static in size. The swelling does not interfere with her activities of daily living except if she uses the hand in a dorsi- flexed position. What bothers her most is the ugly appearance of the swelling. She cannot remember a traumatic incident which may have given rise to the swelling.

On examination one finds a one and a half by two-centimeter firm swelling just radial to the flexor carpi radialis and proximal to the thenar eminence. The radial artery is clearly palpable and is not involved in the swelling. However one can feel a very slight pulsation with careful palpation of the swelling. The swelling is translucent to light. Furthermore the swelling is not attached to any specific tendon.

Special investigations only included plain x-rays of both hands which included the wrists. This only revealed a swelling of the soft tissue on the lateral view. We did not feel it was necessary to do further special investigations which may have included sonar or MRI, since the clinical diagnosis is clear.

The diagnosis a Volar Ganglion. As

differential diagnosis one could include a lipoma and as a rare possibility an aneurysm of the superficial branch of radial artery.

The management is similar to the dorsal ganglion namely aspiration first. After aspiration a pressure bandage for a few days would be appropriate. The aspirate which should be clear jelly-like fluid will confirm a volar ganglion. In about 30 % of cases this treatment should be sufficient. Should the swelling return (in about 70 % of cases aspirated) a communicating volar ganglion with the wrist joint is the obvious diagnosis. This communication occurs at scapho- lunate joint of the wrist. The surgical treatment is careful dissection of the ganglion. The pedicle should be followed all the way to the capsule. A 1 x 1 cm section of capsule should be

excised. One should be very careful not to damage the main radial artery or its superficial branch. Sometimes one may find an extension of the ganglion along the flexor carpi radialis as it passes under the thenar muscles on its way to insert on the second metacarpal. This should also be removed. Post-operatively a volar splint for five days should be applied. After removal of the splint the patient is encouraged to mobilize the wrist normally.

Discussion

A volar ganglion is similar to a dorsal ganglion. The etiology is not clear since the fluid in the ganglion is not synovial fluid in any sense. The lining of the ganglion is not synovium but

flattened epithelial cells. It still remains a mystery why the capsule should undergo metaplasia to cause the ganglion.

The slight pulsation that could be felt during examination is due to the transmission of pulsation from the superficial branch of the radial artery. One should also be careful when dissecting the volar ganglion not to damage the superficial cutaneous branch of the median nerve which takes its origin from the median nerve just proximal to the flexor retinaculum. This branch supplies the skin over the thenar muscles on the radial side.

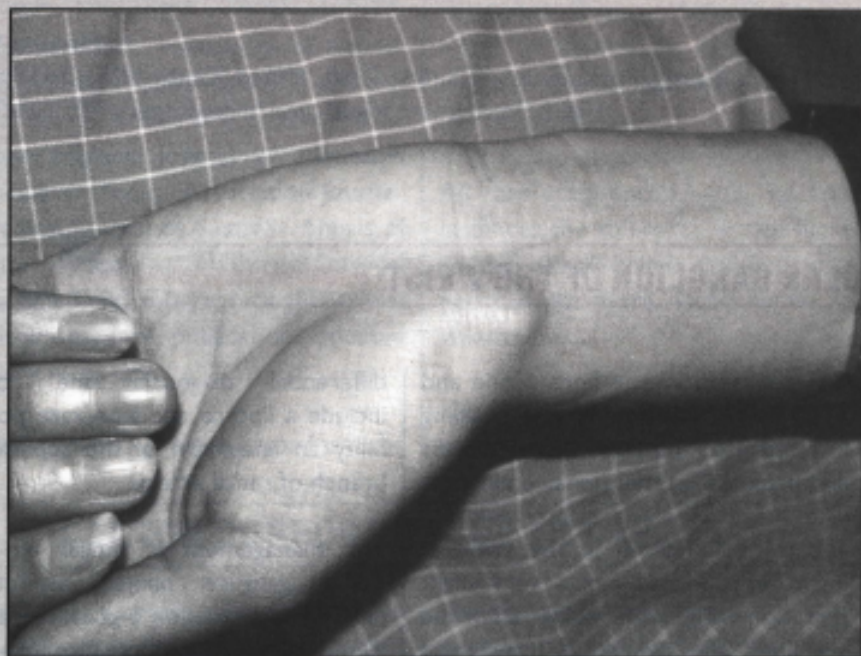
Since fibrous scar tissue occurs after surgery it is extremely difficult to re-

operate a recurring volar ganglion. Therefore, it is especially important when this surgery is performed that the ganglion be removed with a section of the capsule to prevent recurrence. The edges of the capsule should be cauterized as an additional precaution.

Volar ganglions occur mostly in younger females and have no relationships with any other known disease. It further has no relationship to the type of occupation or hand dominance of the patient.

With sincere regards,

Ulrich Mennen



Legend:

The volar ganglion always originates from the scapho-lunate joint. It may have an extension distally along the flexor carpi radialis tendon. Aneurysm of the radial artery, lipoma and tendon synovitis should be included in the differential diagnosis.

DIAGNOSTIC ULTRASOUND SKILLS

90 minutes Training Video
and Atlas

Please phone
Gina:
012-658 0148

JOIN AN ACADEMY MEETING

NEAR YOU



Contact Penny Bryce on
(011) 807 6605
for more information